

Determination of epiphyseal screw lengths in distal radial fractures: A computerized tomography analysis study

Determination of epiphyseal screw lengths in distal radial fractures

Levent Umur¹, Enes Sari²

¹Department of Orthopaedics and Traumatology, Kadikoy Acibadem Hospital, Istanbul, Turkey

²Department of Orthopaedics and Traumatology, Near East University Hospital, Lefkosa, TRNC

Abstract

Aim: The aim of this computerized tomography study was to determine the optimal epiphyseal screw length using the diaphyseal screw length as a reference while performing volar plate osteosynthesis of the distal radius.

Material and Methods: Computerized tomography scans of 49 wrists (35 men and 14 women) were used for the measurements. The mean maximal length of one diaphyseal screw and four distal epiphyseal screws was measured and statistical analyses were performed.

Results: The results of this study revealed that the epiphyseal screw lengths were highly correlated with the diaphyseal screw length. Based on the data derived from measurements, we recommend using epiphyseal screw lengths of 14, 14, 16 and 14 mm for FU, NU, NR and FR screws, respectively, for 10 mm diaphyseal screws, 16, 16, 16 and 14 mm, respectively, for 12 mm diaphyseal screws, and 16, 18, 18 and 16mm, respectively, for 14 mm diaphyseal screws to achieve safe and secure fixation in volar plating of distal radial fractures.

Discussion: Using predetermined epiphyseal screw lengths in volar plating of distal radial fractures may decrease operation time, reduce intraoperative radiation exposure, and avoid the risk of intra-operative or postoperative extensor tendon injury.

Keywords

Radius distal fracture; Volar plate; Screw length; Prediction; Safe surgery

DOI: 10.4328/ACAM.20440 Received: 2020-12-16 Accepted: 2021-01-31 Published Online: 2021-02-09 Printed: 2021-07-01 Ann Clin Anal Med 2021;12(7):751-755

Corresponding Author: Levent Umur, Department of Orthopaedics and Traumatology, Acibadem Kadikoy Hospital, Tekin Street, No:8 Istanbul, Turkey.

E-mail: dr.flumur@gmail.com P: +90 5322017339

Corresponding Author ORCID ID: <https://orcid.org/0000-0003-4961-4508>

Introduction

The volar plate osteosynthesis is a popular treatment option for distal radial fractures. Volar plating of the distal radius may be complicated with irritation and/or rupture of the extensor tendons. Drilling the dorsal cortex or the placement of excessively long epiphyseal screws may cause tendon complications [1]. Although most surgeons rely on the sensation of drilling the dorsal cortex and using depth measuring tools to determine epiphyseal screw lengths, comminution and fragmentation of the dorsal cortex may lead to errors. In addition, evaluation of the epiphyseal screws may be difficult on standard radiographic views due to the trapezoidal shape of the distal radius. Alternative intraoperative fluoroscopic images (skyline view, radial groove view or supinated view) were also defined to detect oversized screws with a sensitivity of 75-85% for 2 mm screw protrusions [2], but drilling depth cannot be determined with these methods [3]. Several authors have recommended the use of unicortical epiphyseal locking screws to avoid dorsal cortex penetration and extensor tendon injury [4, 5]. The unicortical screw length is suggested to be a minimum of 75% of the total thickness of the distal radius epiphysis to maintain reduction [6]. Intraoperative assessment of the screw length with fluoroscopy may not be adequate to avoid excessively long screws. On the other hand, very short screws may cause a loss of reduction.

Recent studies have focused on predicting epiphyseal screw length in volar plating of distal radial fractures in effort to minimize extensor tendon complications. Ljungquist et al. recommended using the lunate depth as an estimate for the length of the longest screw when fixing distal radius fractures with volar plate techniques to avoid extensor tendon irritation and rupture [7]. Similarly, Letissier et al. conducted a radiological study in which computerized tomography scans of 40 patients were virtually plated. They concluded that the epiphyseal screw lengths were highly correlated with the diaphyseal screw length [8].

The aims of this computerized tomography study were as follows: 1. to evaluate a potential relationship between the length of the diaphyseal screw and the lengths of epiphyseal screws in volar plating of distal radial fractures, 2. to offer optimal screw lengths for safe and secure fixation for volar plating of distal radial fractures, 3. to ease the determination process of epiphyseal screw lengths without excessive fluoroscopic exposure for distal radius fractures.

Material and Methods

The shapes of commercially available plates are very similar by means of the positions for epiphyseal and diaphyseal screw holes [8]. Therefore, we conducted this CT analysis study to evaluate the measurements of the distal radius and to determine the screw length applicable to most of the volar plate designs.

Computed tomography (CT) scans of 84 patients from our institution's imaging database from January 2016 to June 2019 were retrospectively evaluated. CT scans of skeletally mature patients without radius pathology were included. Patients younger than 18-years, patients with a radial fracture or anatomic abnormality, and scans with inadequate imaging of

the distal radius were excluded. CT scans of 49 patients (35 men and 14 women) met our inclusion criteria and furtherly evaluated. All scans were performed using a CT scanner (Siemens Somatom Definition Flash, Munich, Germany) for the evaluation of patients with upper extremity trauma. The slice interval of these CT scans was 1 mm. CT images were evaluated using RadiAnt DICOM Viewer (version 4.6.5.18450).

The determination of the epiphyseal and diaphyseal screw holes was as follows: the watershed line was defined as a line, which was drawn parallel to the radiocarpal joint and 4.5 mm proximally to the intersection of the distal radial articular surface and scapholunate joint in coronal and 3-D CT images. The watershed line then was divided into 4 equal quadrants, and the intersection points of these quadrants with the watershed line were marked to mimic 4 epiphyseal screw holes (far ulnar (FU), near ulnar (NU), near radial (NR) and far radial (FR)) in distal radius volar anatomic plate. Plate templates were not used since the screw lengths are not affected by the plate and all commercially available plates provide almost exact epiphyseal and diaphyseal screw locations. An imaginary diaphyseal screw hole (D) of distal radius volar anatomic plate was marked in radial shaft 4 cm proximal to the distal radial articular surface in coronal and 3-D CT images (Figure 1). The watershed line is demonstrated by a yellow line drawn 4.5 mm proximal to the radiocarpal articular surface in all images (a-f). The diaphyseal screw hole is demonstrated with a red dot marked 4 cm proximal to the radiocarpal articular joint (e-f). Epiphyseal screw holes are demonstrated with yellow dots (a. Far Ulnar, b. Far Radial, c. Near Ulnar, d. Near Radial). The projections of the epiphyseal and diaphyseal screw holes were marked also on horizontal and sagittal CT images. The epiphyseal and diaphyseal screw lengths were measured from the near to far cortex on CT images in the sagittal plane. In order to simulate volar plating operation, the epiphyseal screws were given 10 degrees angulation relative to the line, which is perpendicular to the longitudinal axis of the radius in sagittal images (a. Far Ulnar, b. Near Ulnar, c. Near Radial, d. Far Radial, e. Diaphyseal, Yellow line: Watershed line, Blue line: Sagittal plane, Green line: Axial Plane) (Figure 2).

Statistical Analysis

Descriptive parameters and linear regression analysis were used in the statistical evaluation of the data. The normality of the distribution of the study population was verified using the Kolmogorov-Smirnov test. A regression analysis was performed between the maximum lengths of the diaphyseal screw and the distal epiphyseal screw in each region (FU, NU, NR and FR). Statistical significance was set at $p < 0.05$ with a confidence interval (CI) of 95% while evaluating the results. All analyses were performed using IBM SPSS Statistics 22.0.

Results

Linear regression analysis between the diaphyseal screw length and each of the epiphyseal screw length regions showed a linear correlation and resulted in 4 regression equations. The results were statistically significant ($p < 0.05$) with a CI of 95%. The coefficients of correlation values (R) of FU, NU, NR and FR epiphyseal screws were 0.60, 0.59, 0.55 and 0.57, respectively, and the coefficients of determination values (R²) of FU, NU,

Table 1. Linear regression analysis of the data showed high coefficients of correlation values for FU, NU, NR and FR epiphyseal screws (bold and underlined)

		Unstandardized Coefficients		Standardized Coefficients	t	Sig.	95,0% Confidence Interval for B	
		B	Std. Error	Beta			Lower Bound	Upper Bound
Far Ulnar	(Constant)	9,495	1,961	0,598	4,841	0,0001	5,55	13,441
	Diaphyseal	0,787	0,154		5,12	0,0001	0,478	1,097
Near Ulnar	(Constant)	9,37	2,244	0,586	4,176	0,0001	4,856	13,885
	Diaphyseal	0,871	0,176		4,954	0,0001	0,517	1,225
Near Radial	(Constant)	12,355	1,85	0,553	6,678	0,0001	8,633	16,078
	Diaphyseal	0,66	0,145		4,549	0,0001	0,368	0,951
Far Radial	(Constant)	10,165	1,777	0,565	5,721	0,0001	6,591	13,739
	Diaphyseal	0,653	0,139		4,689	0,0001	0,373	0,933

Table 2. Recommended epiphyseal (FU, NU, NR, FR) screw lengths according to diaphyseal (D) screw lengths

D	FU	NU	NR	FR	
10	17,40	18,07	18,96	16,66	Maximum
	14,79	15,35	16,11	14,16	85%
	13,00	13,55	14,22	12,49	75%
	14	14	16	14	Recommended
12	18,98	19,81	20,28	17,96	Maximum
	16,13	16,83	17,23	15,26	85%
	14,23	14,85	15,21	13,47	75%
	16	16	16	14	Recommended
14	20,56	21,55	21,60	19,26	Maximum
	17,47	18,31	18,36	16,37	85%
	15,42	16,16	16,20	14,44	75%
	16	18	18	16	Recommended

NR and FR epiphyseal screws were 0.36, 0.34, 0.31 and 0.32, respectively (Table 1). The maximum length of epiphyseal screws of FU, NU, NR and FR were found as 17.4, 18.07, 18.96 and 16.66 mm for 10 mm diaphyseal screw, 18.98, 19.81, 20.28 and 17.96 mm for 12 mm diaphyseal screw, and 20.56, 21.55, 21.6 and 19.26 mm for 14 mm diaphyseal screw, respectively.

Discussion

The results of this CT analysis study revealed that there was a statistically significant correlation between the diaphyseal screw length and the epiphyseal screw lengths in volar plating of distal radial fractures. The regression analysis showed high coefficients of correlation values ($R > 0.5$) for each epiphyseal screw region. In order to limit the risk of dorsal cortex penetration and achieve optimum strength for fixation, in the literature, it is shown that epiphyseal unicortical locking screws should be at least 75% in length to produce stability similar to bicortical fixation [9]. Therefore, in our study, epiphyseal screw measurements were recalculated and determined to be between 75% and 85% of maximum epiphyseal screw lengths and rounded down to commercially available screw sizes (Table 2). The results of this study suggest the use of epiphyseal screw lengths of 14, 14, 16 and 14 mm for FU, NU, NR and FR screws, respectively, for 10 mm diaphyseal screws, 16, 16, 16 and 14 mm, respectively, for 12 mm diaphyseal screws, and 16, 18, 18

and 16mm, respectively, for 14 mm diaphyseal screws.

The use of these predetermined lengths may help the surgeon avoid the risk of dorsal cortex penetration and therefore minimize the complication of extensor tendon injury. There are novel studies to prevent these complications, such as using intraoperative computed tomography-guided navigation systems, and all efforts of the researchers aimed at preventing dorsal and intraarticular penetration [10]. Compared to these techniques, the use of predetermined screw lengths may also reduce intraoperative radiation exposure through the use of fluoroscopic imaging. Extensor tendon injuries may also occur with over-drilling of the far cortex [11]. In extraarticular osteoporotic fractures, even if the dorsal cortex is intact, depth measuring and feeling of the dorsal cortex during drilling may be hard. Moreover, dorsal comminution of the distal radius displaces the extensor tendons more anteriorly from their original anatomic position and causes a higher risk for extensor tendon injury. Using predetermined sizes gives surgeons the advantage of using depth stop drill bits to avoid intraoperative tendon injuries by leaving the dorsal cortex intact. Letissier et al. suggested to use 18, 18, 20, and 16 mm epiphyseal screws for FU, NU, NR and FR, respectively, for diaphysis screws shorter than 14 mm, and 20, 20, 22, and 18 mm epiphyseal screws for diaphysis screws of 14 mm or longer in their study of the virtual plating of distal radius [8]. In our study, every radius was evaluated and compared with its own diaphyseal screw length in our study. Therefore, it can be considered that no gender evaluation is needed for the same ethnicity. Conversely, using an equal length of the epiphyseal screw with a 10-mm-diaphysis and a 13.9-mm-diaphysis can cause dorsal cortex penetration or insufficient fixation problems. For this reason, we evaluated the diaphyseal lengths in 3 groups (10-11.9, 12-13.9, 14 and above). Yuen et al. reported that the mean FU, NU, NR and FR screw lengths were 20 mm, 20.8 mm, 19.6 mm and 15.4 mm, respectively, in their cadaveric study [12]. In our study, the measurements of the distal radial epiphysis thickness were in concordance with these previous studies. However, we suggest using screw lengths between 75% and 85% of bicortical measurements for safe (avoiding dorsal cortex penetration) and secure (avoiding secondary loss of reduction) fixation.

This study has some limitations. First of all, we conducted a

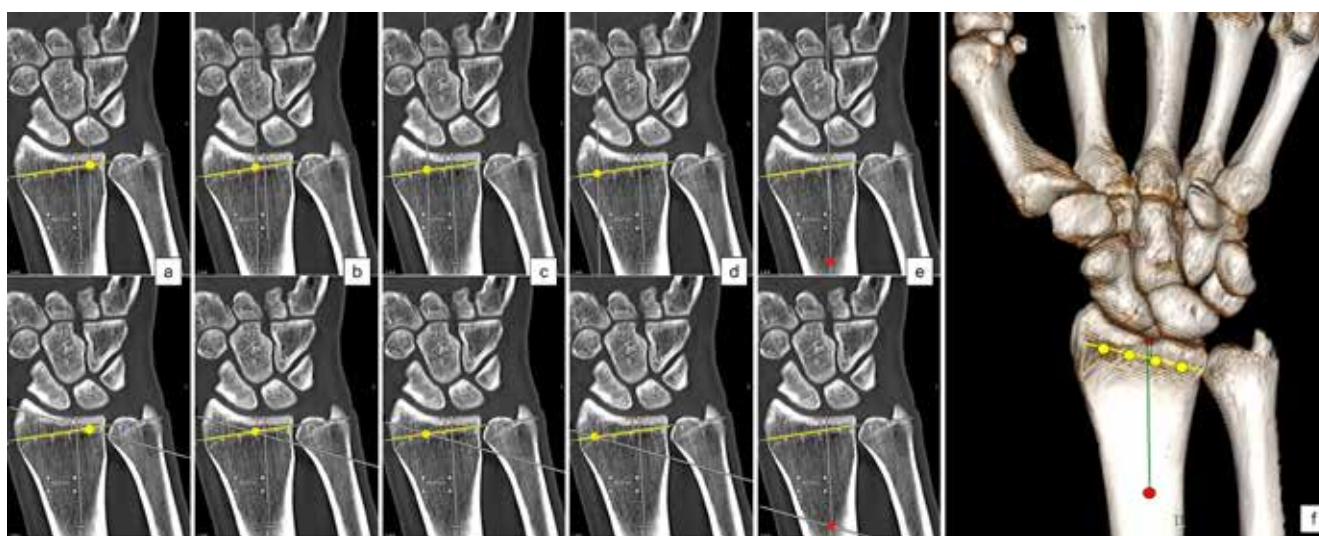


Figure 1. Determination of watershed line, epiphyseal and diaphyseal screw holes in coronal (a-e) and 3-D (f) CT images.

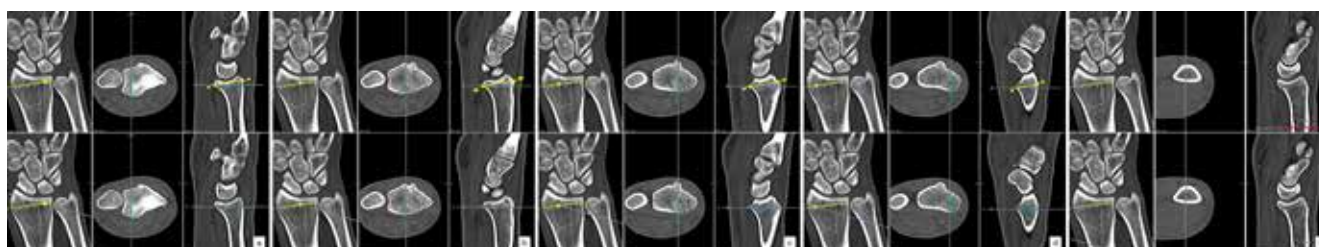

Figure 2. Measuring epiphyseal (a-d, yellow line with dots) and diaphyseal (e, red line with dots) screw lengths.

CT analysis study to determine the epiphyseal screw lengths, not specific to any commercial plate design, but which may be applicable to most of the available plates. This may seem like a potential error, but we think that the measurements of the distal radius may be a valuable guide for surgeons, since the screw length measured cortex to cortex in locking plates, to avoid tendon complications while performing volar plate surgery. Previous studies have measured the length of the epiphyseal screws placed perpendicular to the plate [11]. In this study, measurements were made for screws with a fixed 10 degrees angulation. Screw angulation can be manipulated in several commercially available plates, thus may alter the epiphyseal screw lengths. Additionally, we designed our study to position epiphyseal screws 4.5 mm proximal to the radiocarpal joint line. More proximal placement of the volar plate may also alter screw lengths. Moreover, it should be kept in mind that ethnicity changes may result in different anatomic features, and therefore measurements may differ. This technique may not be practical for the surgeons preferring to apply the distal epiphyseal screws first as an aid for reduction. On the contrary, a predetermined screw length can be a helpful guide for safe screw placement and secure fixation.

Conclusion

We recommend to use epiphyseal screw lengths of 14, 14, 16 and 14 mm for FU, NU, NR and FR screws, respectively, for 10 mm diaphyseal screws, 16, 16, 16 and 14 mm, respectively, for 12 mm diaphyseal screws, and 16, 18, 18 and 16mm, respectively, for 14 mm diaphyseal screws to achieve safe and secure fixation in the volar plating of distal radial fractures. Using predetermined epiphyseal screw lengths in volar plating

of distal radial fractures may avoid the risk of extensor tendon injury, decrease operation time and reduce intraoperative radiation exposure.

Scientific Responsibility Statement

The authors declare that they are responsible for the article's scientific content including study design, data collection, analysis and interpretation, writing, some of the main line, or all of the preparation and scientific review of the contents and approval of the final version of the article.

Animal and human rights statement

All procedures performed in this study were in accordance with the ethical standards of the institutional and/or national research committee and with the 1964 Helsinki declaration and its later amendments or comparable ethical standards. No animal or human studies were carried out by the authors for this article.

Funding: None

Conflict of interest

None of the authors received any type of financial support that could be considered potential conflict of interest regarding the manuscript or its submission.

References

1. Dolce D, Goodwin D, Ludwig M, Edwards S. Intraoperative evaluation of dorsal screw prominence after polyaxial volar plate fixation of distal radius fractures utilizing the Hoya view: a cadaveric study. *Hand*. 2014;9(4):511-15.
2. Stoops TK, Santoni BG, Clark NM, Bauer AA, Shoji C, Schwartz-Fernandes F. Sensitivity and Specificity of Skyline and Carpal Shoot-Through Fluoroscopic Views of Volar Plate Fixation of the Distal Radius: A Cadaveric Investigation of Dorsal Cortex Screw Penetration. *Hand*. 2017;12(6):551-6.
3. Haug LC, Glodny B, Deml C, Attal R. A new radiological method to detect dorsally penetrating screws when using volar locking plates in distal radial fractures: The dorsal horizon view. *Bone Joint J*. 2013;95B(8):1101-5.
4. Dardas AZ, Goldfarb CA, Boyer MI, Osei DA, Dy CJ, Calfee RP. A Prospective Observational Assessment of Unicortical Distal Screw Placement During Volar Plate Fixation of Distal Radius Fractures. *J Hand Surg Am*. 2018;43(5):448-54.
5. Seki Y, Aoki T, Maehara H, Shirasawa S. Distal locking screw length for volar locking plate fixation of distal radius fractures: Postoperative stability of full-length unicortical versus shorter screws. *Hand Surg Rehabil*. 2019;38(1):28-33.
6. Wall LB, Brodt MD, Silva MJ, Boyer MI, Calfee RP. The effects of screw length on stability of simulated osteoporotic distal radius fractures fixed with volar locking plates. *J Hand Surg Am*. 2012;37(3):446-53.

7. Ljungquist KL, Agnew SP, Huang JI. Predicting a safe screw length for volar plate fixation of distal radius fractures: Lunate depth as a marker for distal radius depth. *J Hand Surg Am.* 2015;40(5):940-4.
8. Letissier H, Dardenne G, Stindel E, Borotikar B, Le Nen D, Kerfant N. Predicting epiphyseal screw length in anterior plating of distal radial fractures. *J Hand Surg Eur.* 2020;45(4):354-9.
9. Im JH, Lee JY. Pearls and Pitfalls of the Volar Locking Plating for Distal Radius Fractures. *J Hand Surg Asian Pac Vol.* 2016;21(2):125-32.
10. Kaneshiro Y, Hidaka N, Yano K, Kawabata A, Fukuda M, Sasaoka R, et al. Intraoperative computed tomography with an integrated navigation system versus freehand technique under fluoroscopy in the treatment of intra-articular distal radius fractures. *J Plast Surg Hand Surg.* 2019;53(5):255-9.
11. Synek A, Borgman L, Traxler H, Huf W, Euler E, Chavalier Y, et al. Using self-drilling screws in volar plate osteosynthesis for distal radius fractures: A feasibility study. *BMC Musculoskelet Disord.* 2016;17(1):1-7.
12. Yuen G, Yee DKH, Fang C, Lau TW, Leung F. Screw length in volar locking plate fixation for distal radial fractures. *J Orthop Surg.* 2015;23(2):164-7.

How to cite this article:

Levent Umur, Enes Sari. Determination of epiphyseal screw lengths in distal radial fractures: A computerized tomography analysis study. *Ann Clin Anal Med* 2021;12(7):751-755